

SARASWATI DENTAL
COLLEGE,
FAIZABAAD ROAD

SDC BULLETIN



1 JAN 2012

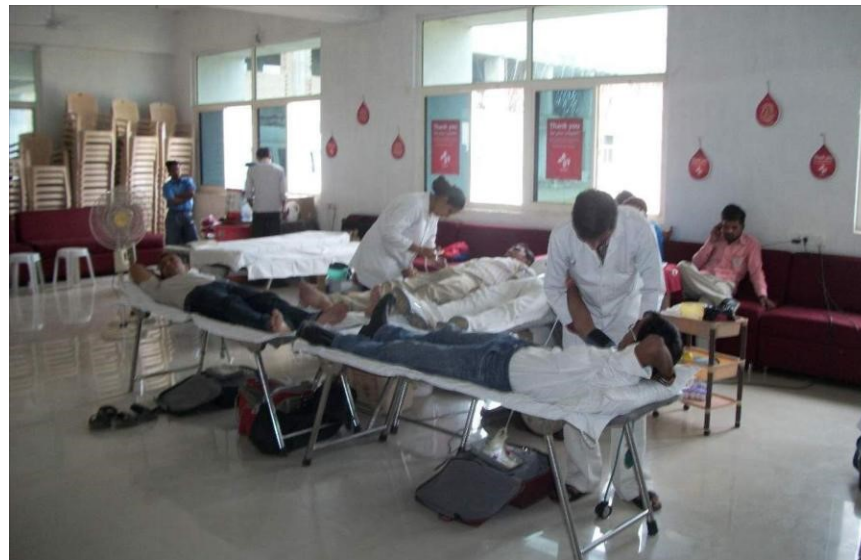SPECIAL POINTS OF IN- TEREST:

- Go Green tree plantation
- Launching of SDC Portal.com
- Inspections in various Department
- Letter writing Marathon
- PULSE 2011

INSIDE THIS ISSUE:

- Publications of the issue 2
- Case of the issue 2
- Suggestive Reading 2
- Foundation Day Celebrations 3
- Annual sports meet and Rhapsody 2011 3
- Upcoming headlines.. 4

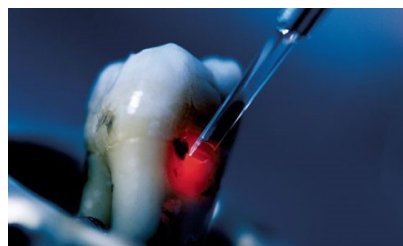BLOOD DONATION CAMP



The Saraswati institute in collaboration with Rotract cub organized a blood donation camp. Total of 200 bottles of blood were donated by the institution. It was a noble cause put forward by various teaching, non teaching staff and by the students.

The blood was donated to Ram Manohar Lohia Hospital and the college was awarded the active participation certificate along with a certificate of appreciation for this cause.

Demonstration of Dental laser..



There was demonstration of dental Lasers by NSK . This demonstration was to help the post graduate students as well as various teachers.


The session also included hands on and various usage of lasers in dentistry with explaining various pros n cons of the equipments.

Publications of the issue:



- Bahuguna R, Jain A, Khan SA. Early dental visit - An overview. *Asian J Oral Health Allied Sci* 1(1):58-60, 2011.
- Bedi RS, Goel P, Goel A, Pasricha N. Osteoma of maxillary sinus - A rare case report. *Asian J Oral Health Allied Sci* 1(1):40-43, 2011.
- Gera T, Manjunath MK, Loomba K. An in vitro study of shaping ability of two rotary endodontic instruments in curved roots canals. *Asian J Oral Health Allied Sci* 1(1):85-90, 2011.
- Reddy CHU. Wisdom tooth: A source of stem cells. *Asian J Oral Health Allied Sci* 1(1):83-84, 2011
- Gupta LC, Kohli M, Punn K, Abhishek. Use of buccal fat pad in Oral Sub Mucous Fibrosis - A case report. *Asian J Oral Health Allied Sci* 1(1):51-52, 2011.
- Khan SA, Khan SY, Bahuguna R. Evaluation of caries experience with oral health Practices in Lucknow children. *Asian J Oral Health Allied Sci* 1(1):13-16, 2011.
- Loomba K, Bains R, Loomba K, Ganesan S, Bains VK. Sinus tract mimicry: A case report. *J Oral Health Comm Dent* 5(10):52, 2011
- Loomba A, Agarwal P, Upadhyay U, Goel A, Sohal V. Arch perimeter: A comparative study. *Asian J Oral Health Allied Sci* 1(1):1-3, 2011.
- Shrivastava S, Ramkrishna A, Sahu A. The papillon lefevre syndrome in two sisters. *Int J Dent Clin* 3(4):33-36, 2011
- Agarwal N, Mathur S, Agarwal K, Khan M. Cleidocranial Dysplasia - A case report. *J Oral Sign* 3(3):164-167, 2011
- Agarwal N, Raj V, Mathur S, Agarwal K. Myiasis of oral cavity - A case report. *Clinical Dentistry - National J Indian Dental Assoc* 5:38-40, 2011
- Bahuguna R, Narain S, Singh T. Dental caries leading to premature loss of baby teeth: Implication and management. *Indian J Comm Health* 23(2):107-108, 2011.
- Bains VK, Gupta V, Singh GP, Bains R. Mucogingival surgery: Where we stand today? *J California Dent Assoc* 39(8):573-583, 2011.
- Bhalla H, Pant KK, Dikshit M, Surin M, Singh MM. Effect of ormeloxifene, a nonsteroidal once-a-week oral contraceptive, on systemic hemodynamics in adult female rats. *J Pharmacol Pharmacotherap* 2, 90-94, 2011.
- Chandra S. Effect of duration of pan masala chewing habit on mouth opening. *J Indian Dent Assoc* 5:21-22, 2011.

Case of the issue::



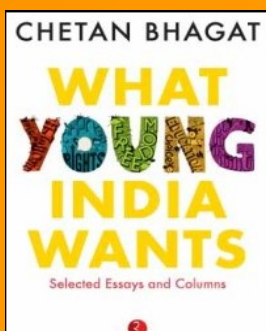
Pre treatment



Post treatment

Female patient Rohini of age 23 years came to the department of orthodontics with the chief complaint of forwardly placed teeth. The case was studied after taking the preliminary records. The records included complete sets of photographs, X-rays and study models. The detailed case history and patients expectation from the treatment was also were recorded. After preparing the problem list orthognathic surgery was planned for the patient. The case was started by putting a basic orthodontic fixed appliance for the patients. Before doing the surgery it was planned to decompensate the malocclusion the decompensation or the presurgical phase continued for nearly six months after which the surgery was done. The patient had to come to the department again for the postsurgical orthodontic phase. The post surgical orthodontic phase continued for another four months in which the minor correction in the occlusion were done. The overall result was very satisfying for the patient as well as the doctor's team. In this case the surgical correction was required to correct the skeletal discrepancy where as the dental correction was done with the orthodontic fixed appliance.

Suggestive Reading ::

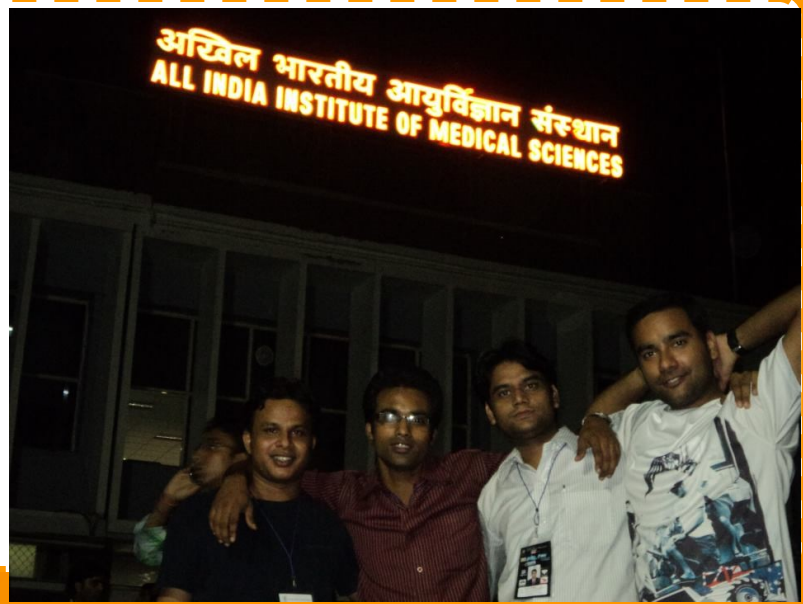

It is the only non-fiction book by Chetan Bhagat and is the compilation of his speeches and essays. It includes various topics ranging from Indian politics, Indian society and young Indians. The book revolves around the author's thoughts and innovations on how to improve the Indian economy through social reforms. The book criticizes the dis-function of the Indian government as well as the moralities regarding the current condition of the country in the author's version of India, every problem's root is basically a lack of opportunity, issues of caste and religion and vote bank politics. The author in this book, talks about the corruption in India and how the society should change to rid it.

INDEPENDENCE DAY



Top to Bottom: 1. Flag Hoisting 2. Singing of the National Anthem 3. Speech by Dr.(Col.) T.S.Mathur.



Pulse 2011. The college students went for inter college events at AIIMS , Delhi, under the guidance of Dr. Amit Ambuj. We won many prizes along with the best "Runner's Sheild " given to Dr.Nitish.

Upcoming Events ...

1. Amistad "2012".
2. DCI Inspections
3. Distribution of free medicines in the camp
4. Starting of Lectures on management and various business techniques favorable for doctors in corporate world.



Tarushi Saighal, Akash Sethi and Prathna Dalmia

THE EDITORIAL BOARD ::

Dr. Alka Yadu
Dr. Pratik Chandra
Dr. Saurabh Mathur
Dr. Abhishek Gaur

Disha Goyal
Sneha Mehrotra
Ashutosh Pandey
Neha Bajpai
Paridhi Mehra
Mithali Kaushik
Nitish Jhunjhunwala