

SARASWATI DENTAL
COLLEGE,
FAIZABAAD ROAD

SDC BULLETIN



I SEP 2010

SPECIAL POINTS OF IN- TEREST:

- Orientation of PG Batch
- Inspection of DCI in Department of Prosthodontics
- Farewell to Dr. Atul Bhatnagar
- Formulation of Scientific Committee

INSIDE THIS ISSUE:

- Publications of the issue 2
- Case of the issue 2
- Suggestive Reading 2
- Hepatitis B 3rd dose 3
- Creative Writing 3
- Upcoming headlines.. 4

The Rotract Club

Rotract Club of Saraswati Lucknow is a part of Rotary International, an endeavor taken up by the students of Saraswati Dental College for Public service as a tribute to the humanity. The club came into existence in the Rotary Year 2002-03, under the leadership of Dr. R. M. Mathur who was the president of the sponsoring Rotary Club Lucknow Rajdhani. It is an institutional based club in which students of Saraswati Dental College who are interested in the activities of the Rotract can become its members. The office bearers are selected by the principal of the institute on the basis of their academic, co-curricular records and interest shown in the Rotract activities.

2010-11
Deepak Singh
(President)
Aman Bhamri
(Secretary)

The maiden year 2002-03 proved to be a golden year with the charter membership of 109 members. The Club became the largest not only in India but in the south Asia region as stated and recognized in the district meet.

Office Bearers of Rotract Club Saraswati Dental College, Lucknow ::

Deepak Singh (President) and Aman Bhamri (Secretary)



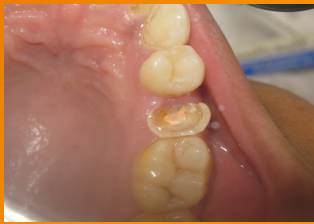

Publications of the issue:

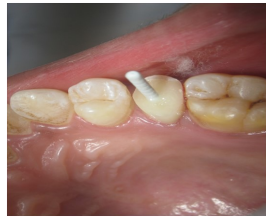- Bains R, Jethwani GS, Loomba K, Loomba A, Dubey OP, Bains VK. Taurodontism: A case report of morpho-anatomical variant. Endodontic Practice Today 4(4):301-304, 2010.
- Gupta V, Gupta B. Probiotics and periodontal disease: A current update. J Oral Health Comm Dent 4 (Spl):35, 2010
- Kohli M, Kohli M, Sharma N, Siddiqui SR, Tulsii SPS. Gorlin-Gofez syndrome. J Maxillofac Oral Surg 8(4):50, 2010
- Raj N, Aeran H, Dhir RC, Raj V. Complete dentures for a patient with maxillary hemangioma – A case report. Clin Dent Mumbai June:10, 2010

Case of the issue::

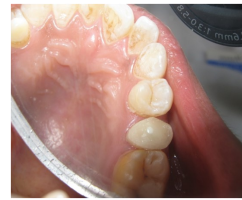FIBRE POST irt 15



PRE OPERATIVE



POST CEMENTATION
AND CORE BUILDUP



POST OPERATIVE

A 22 year old female patient came with a chief complaint of hollow teeth . on examination, the patient was diagnosed with chronic irreversible pulpitis with grossly decayed tooth . The line of treatment followed was root canal procedure followed by post cementation. Palatal canal was chosen since the loss was more on the palatal surface. Tooth no. 15 was root canal treated followed by fibre post placement in the palatal canal and was further built up with dual cure composite.




Suggestive Reading ::

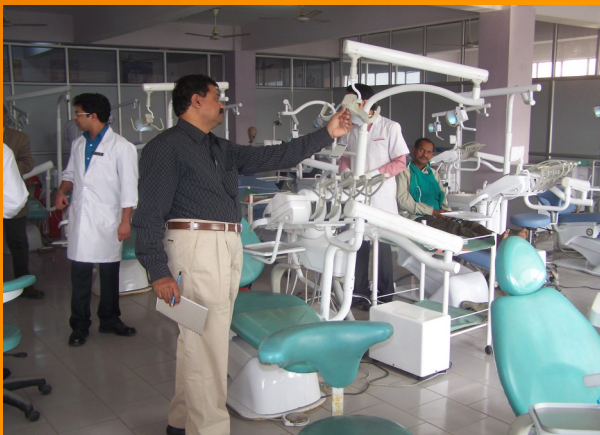Amish makes the premise that Shiva is a man and that there are no magical gods when writing his trilogy. The story starts off with Shiva coming to the plains from the banks of the Mansarovar to fulfil his destiny of rid-

ding the world of evil. On drinking somras, the elixir of those times, his throat turns blue and people bow to the Neelkanth who has come to save them. Only the Neelkanth is reluctant to believe he is the saviour of the peo-

ple and there starts the story of Shiva, who from a mere man becomes the Mahadev. Evil is not a person, it is an idea or belief.



INSPECTION OF THE DEPARTMENT OF PROSTHODONTICS



ANATOMY:

Life arises as a result of fusion ,
Within the wall of fallopian tube,
Its ways are crooked and tortuous,
Like the glands of uterus.
For some , its hollow,
Like the pits of Fundus
And for others , the meaning is deeper,
Like the ones of Pylorus.

Like the slides of histology.
It is difficult to remember, and
Like the course of vagus , it is sinister.
The pumping heart represents hope,
Against failing optimism, one has to cope
Failure is the only developmental anomaly
And success is a result of organs
Working in a harmony.



Display of Dental Material exhibition room to the presidents of DCI.



Upcoming Events ...

1. Arrival of Red Ribbon Express...
2. Talent hunt at MB Club.
3. Internal Assessment
4. Rhapsody 2010
5. Book exhibition...



Dr. Rajat Mathur , Dr. Rahul Bihari explaining the various models kept in the museum of Dental Material.

THE EDITORIAL BOARD ::

Dr. Alka Yadu
Dr. Pratik Chandra
Dr. Saurabh Mathur
Dr. Abhishek Gaur

Disha Goyal
Sneha Mehrotra
Ashutosh Pandey
Neha Bajpai
Paridhi Mehra
Mithali Kaushik
Nitin Jhunjhunwala