

SARASWATI DENTAL  
COLLEGE,  
FAIZABAAD ROAD

# SDC BULLETIN



I SEP 2012

## SPECIAL POINTS OF INTEREST:

- Introductory session and orientation of new batch (2012-2013)
- Internal Assessment
- Citation of Appreciation of Retract Secretaries
- DCI Inspection

## Introduction of the New Batch (2012-2013)

### INSIDE THIS ISSUE:

- Publications of the issue 2
- Case of the issue 2
- Suggestive Reading 2
- DCI Inspection 3
- Upcoming headlines.. 4



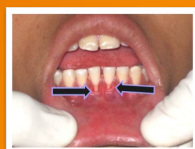
The new batch is formally introduced with the college environment. A senior doctor headed by group of students introduces the fresher students to the college environment, to the subjects, various areas in the college which all subjects they will encounter through all their undergraduate years and how to maintain the decoram

# Publications of the issue:

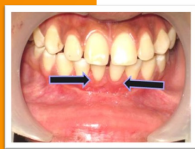

- Agrawal S, Singh D. Clinical applications of cone-beam computed tomography in periodontics. GUIDENT 5(12):67-70, 2012.
- Bains R, Bains VK, Loomba K, Verma K, Nasir A. Management of pulpal floor perforation and grade II furcation involvement using mineral trioxide aggregate and platelet rich fibrin: A clinical report. *Contemp Clin Dent* 3, Supplement 2:S223-S227, 2012.
- Chana S, Mathur R, Singh MM. Metals in your denture – How safe? *Science Reporter (NISCAIR, CSIR, New Delhi, India)* 49:53-57, 2012.
- Chandra P, Agrawal S. Intraoral molar distalization – Review. *Philippines J Orthodont* 11(1):34-41, 2012.
- Kar SK, Tripathi A, Singh SV. Using neutral zone and mandibular guidance concept to restore aesthetics and function in a hemi-mandibulectomy patient. *Indian J Dent Adv* 4(2):875-879, 2012
- Loomba A, Goel A, Verma P. Quantitative analysis of Nickel Titanium Arch Wires. *J Indian Orthodont Soc* 46(4):92-98, 2012
- Khan SA, Khan SY, Bains VK, Bains R, Loomba K. Dens Invaginatus: Review, relevance, and report of 3 cases. *J Dent Children* 79(3):143-153, 2012.
- Kumar N, Srivastava S, Majumdar DSP, Loomba K. Veneer in restorative dentistry. *Asian J Oral Health Allied Sci* 2(1):17-25, 2012.
- Kumar N, Bains R, Loomba K, Jain A. Mineral Trioxide Aggregate (MTA): A hope for root fracture. *Asian J Oral Health Allied Sci* 2(1):55-58, 2012.
- Pasricha N, Nagar A, Bedi RS, Gupta A, Punj K. Anatomical perspective of Eagle's Syndrome: Review and a case report. *Asian J Oral Health Allied Sci* 2(1):35-39, 2012.
- Raj N, Raj V, Aeran H. Interim palatal lift prosthesis as a constituent of multidisciplinary approach in the treatment of velopharyngeal incompetence. *J Adv Prosthodont* 4:243-247, 2012 (<http://dx.doi.org/10.4047/jap.2012.4.4.243>).
- Rajguru JP, Masthan KMK, Thirugnanasambandan TS, Babu NA. Programmed self-cell suicide (apoptosis) – Current review, concepts and future prospects. *Indian J Multidisciplin Dent* 2(3):500-506, 2012
- Singh BP, Pradhan KN, Tripathi A, Tua R, Tripathi S. Effect of sociodemographic variables on complete denture satisfaction. *J Adv Prosthodont* 4:43-51, 2012.
- Singh N, Agarwal S, Bhagchandani J, Chandra P, Gaur A. Painless anesthesia: A new approach. *J Dentofac Sci* 2(2):49-55, 2012.
- Singh P, Singh A. Central giant cell granuloma of the maxilla: A case report and review of literature. GUIDENT 5(12):75-77, 2012.
- Singhal P, Srivastava AK, Chopra J, Mahdi AA, Srivastava AK. Effect of electromagnetic radiation of mobile phone on sperm morphology in albino rats. *J Anat Sci* 20(2):58, Abstr 52, 2012 (Abstract only).

## Case of the issue::



Pre-operative



Post-operative (6 months)

A 26-year-old female patient reported to the Department of Periodontology, Saraswati Dental College, Lucknow with the chief complaint of hypersensitivity and unesthetic appearance of lower front teeth since 6 months. The patient presented with recession on teeth 31 and 41 along with insufficient attached gingiva and high frenum attachment. An arc-shaped incision was given and a Split thickness bridge flap was mobilized and repositioned coronally with independent sling sutures. The post operative evaluation after 6 months showed complete 100% root coverage.


बूढ़ी काकी  
प्रेमचन्द



## Suggestive Reading ::

The novel is about an old, widowed lady who bequeaths all her possessions to her nephew and his wife but as soon as she does that, the inheritors starts ill-treating her to a extent that she is not even given food to eat. A very poignant depiction of the old lady and her helplessness and grievance, the novel is easily able to move the reader. How she crawl to eat and how the child of the nephew helps her in her distress along with the change in the Mindset of the nephew's wife, are few of the stand-still and spellbound moments in the story, where tears speaks. Published first in 1921, the novel may seem a bit out of place regarding the current generation's choice of literature, but there's a lot to imbibe from this meticulously written peice of Premchand. The obvious lesson to learn is to respect our elders. Another gem from Premchand's writings, the story also throws light on wastage of food in the parties and gatherings.





# DCI Inspection in Department of Conservative Dentistry



The college observed DCI Inspection in the Department of Conservative Dentistry. The Department followed the rules and norms as per DCI norms and the inspection went with any flaws. As a result of which the seats for post graduates were increased to six, which was a very big achievement for the college. The college now offers six post graduate seats in the department of conservative dentistry. The inspection took place under the guidance of Dr. Kapil Loomba as the Head of Department.

## KNOWING PEOPLE THROUGH BLOOD GROUPS:

**GROUP A:** People are perfectionist. Always alert, understand other well outspoken and social in nature. Strong sense of responsibility, win other's TRUST. Optimistic.

**Group B:** People of considerable action, rarely sit, always make plans. Hate being restricted to dull jobs. Have disregard for authority that makes them great innovators. They have their own way of living. Their character is rich in creative and original ideas.

**GROUP O:** Innocent in good sense. They can always get away after being impolite because of their innocent looks. Romantic and realistic. Reveal in work and there is hardly they cannot do with their open eyes and alert brains.

**GROUP AB:** Ultra sensitive and over react emotionally. Success in life often depends on close friends. Can easily adopt themselves and finally get what they want. Often mistaken to be unfriendly and un trustworthy.



Visit by DCI Inspectors to central library.

## Upcoming Events ...

1. Visit by Kmal Hassan
2. Talent hunt
3. Inter city Retract meet at Varanasi
4. Collaboration with Big Bazaar for dental camp organization



Dr. R.S. Bedi principal leading the inspectors through central library.

### THE EDITORIAL BOARD ::

Dr. Alka Yadu  
Dr. Pratik Chandra  
Dr. Saurabh Mathur  
Dr. Abhishek Gaur

Disha Goyal  
Sneha Mehrotra  
Ashutosh Pandey  
Neha Bajpai  
Paridhi Mehra  
Mithali Kaushik  
Nitin Jhunjhunwala