

**SARASWATI DENTAL  
COLLEGE & HOSPITAL,  
FAIZABAD ROAD,  
LUCKNOW**

# SDC BULLETIN



VOLUME 4, ISSUE 2

1 MAY 2014

## INSIDE THIS ISSUE:

Publications of the Issue	2
Case of the Issue	2
Suggestive Reading	2
3rd Alumni Meet	3
Upcoming Headlines	4

## DRAFT GUIDELINES ON AUDIO-VISUAL RECORDING OF INFORMED CONSENT PROCESS IN CLINICAL TRIALS

[www.cdsc.nic.in](http://www.cdsc.nic.in)

Dated: 09/01/2014

The Hon'ble Supreme court, CDSCO vides F. No. GCT/20/SC/Clin./2013 DCG1 dated 19.11.2013 has issued direction that in all clinical trials, in addition to the requirement of obtaining written informed consent, audio-visual recording of the informed consent process of each trial subject, including the procedure of providing information to the subject and his/her understanding on such consent is required to be done while adhering to the principles of confidentiality. Such audio-visual recording and related documentation would be preserved. This is applicable to the new subjects to be enrolled in all clinical trials including Global Clinical Trials.

**“Try not to become a man of success but a man of value”  
-Albert Einstein**

## CDE: 'IMPLANTS'



Inauguration



Participants



Dr. Rohit Madan, Sr. Lecturer, delivering lecture on Complications & Maintenance of Dental Implants



Dr. Shoaib Sheikh, Professor, delivering lecture on Surgical Implications of Dental Implants



Dr. Sushil Kar, Reader, delivering lecture on Prosthetic Implications of Dental Implants



A participant attending Hands-on Workshop on Dental Implants

**CDE Program was organized on 29 March 2014. Various Guest Speakers shared their experience on Dental Implants with the Ex and the Present Students**



1. Tripathi Arvind, Gupta Ashutosh, Gautam Vivek, Md. Anwar, Arora Varun. The efficacy of guide flange prosthesis in correcting mandibular deviation in hemimandibulectomy patients; a correlative study. Journal of Prosthodontics accepted for publication January 2014.
2. Mathur A, Srivastava AK, Singh A. Molecular mechanisms of Japanese encephalitis virus and host interaction. Indian Journal of Scientific Research 2014;Spl Ed:1-8.
3. Gupta B, Tiwari B, Raj V, Kashyap B, Chandra S, Dwivedi N. Transparent tooth model: A study of root canal morphology using different reagents. Eur J Gen Dent 2014;3:66-70.
4. Loomba K, Bains R, Bains VK, Loomba A. Proposal for clinical classification of multifactorial noncarious cervical lesions. General Dentistry 2014;2:39-44.
5. Madan R, Mohan R, Bains VK, Gupta V, Singh GP, Madan M. Analysis of Socket preservation using Polylactide and Polyglycolide (PLA-PGA) Sponge: A clinical, radiographic, and histologic study. The International Journal of Periodontics & Restorative Dentistry 2014;34(2):e36-e42 (Impact Factor 1.08).
6. Mishra V, Mishra M, Chaudhari BP, Khanna R, Das M. Argemone oil and butter yellow induced toxicity in hepatic and extra hepatic tissues. Bioenergetics 2014;3:111.
7. Sinha S, Raghuvanshi M. Oral infection – A risk factor for systemic diseases. Journal of Dentofacial Sciences. 2014;3(1):1-4.
8. Sidhu R, Chandra S, Devi P, Taneja N, Sah K, Kaur N. Forensic importance of maxillary sinus in gender determination: A morphometric analysis from Western Uttar Pradesh, India. Eur J Gen Dent 2014;3(1):53-56.
9. Chandra S, Raju S, Sah K, Anand P. Traumatic ulcerative granuloma with stromal eosinophilia. Archives of Iranian Medicine 2014;17(1):91-94 (Impact Factor 1.22).

## Case of the Issue



Pre-Treatment




Post-Treatment

A patient Ashutosh Kumar 12 year old boy reported to the Department of Orthodontic with the chief complaint of forwardly placed upper teeth. Complete set of records were prepared. Case was studied in detail and it was found that the problem was mainly in the lower jaw as it was short. The patient was still in the growing age so growth modification was planned. It was decided to modify the growth of the mandible with a twin block appliance. The appliance was fabricated and the patient was instructed to wear the appliance full time. Good results were obtained as the patient was very co-operative and wore the appliance religiously.

## Suggestive Reading

This novel raises issue of divorce and how the personality of children is churned as a consequence of the divorce of parents. It often happens that the divorced parents use their child as a weapon against each other. The protagonist of the story, Bunty, a 9 year old child, is caught between the divorce of his parents. How he sees his world crumbling around him without having any idea of why is this happening, is very well portrayed by the author. At the end, its nobody's fault, but that of circumstances, that make Bunty a loved but unacceptable child. Author easily and very swiftly catches the nerve of the reader with her sensitive and emotional portrayal of the protagonist. A must read for readers who prefer this genre.





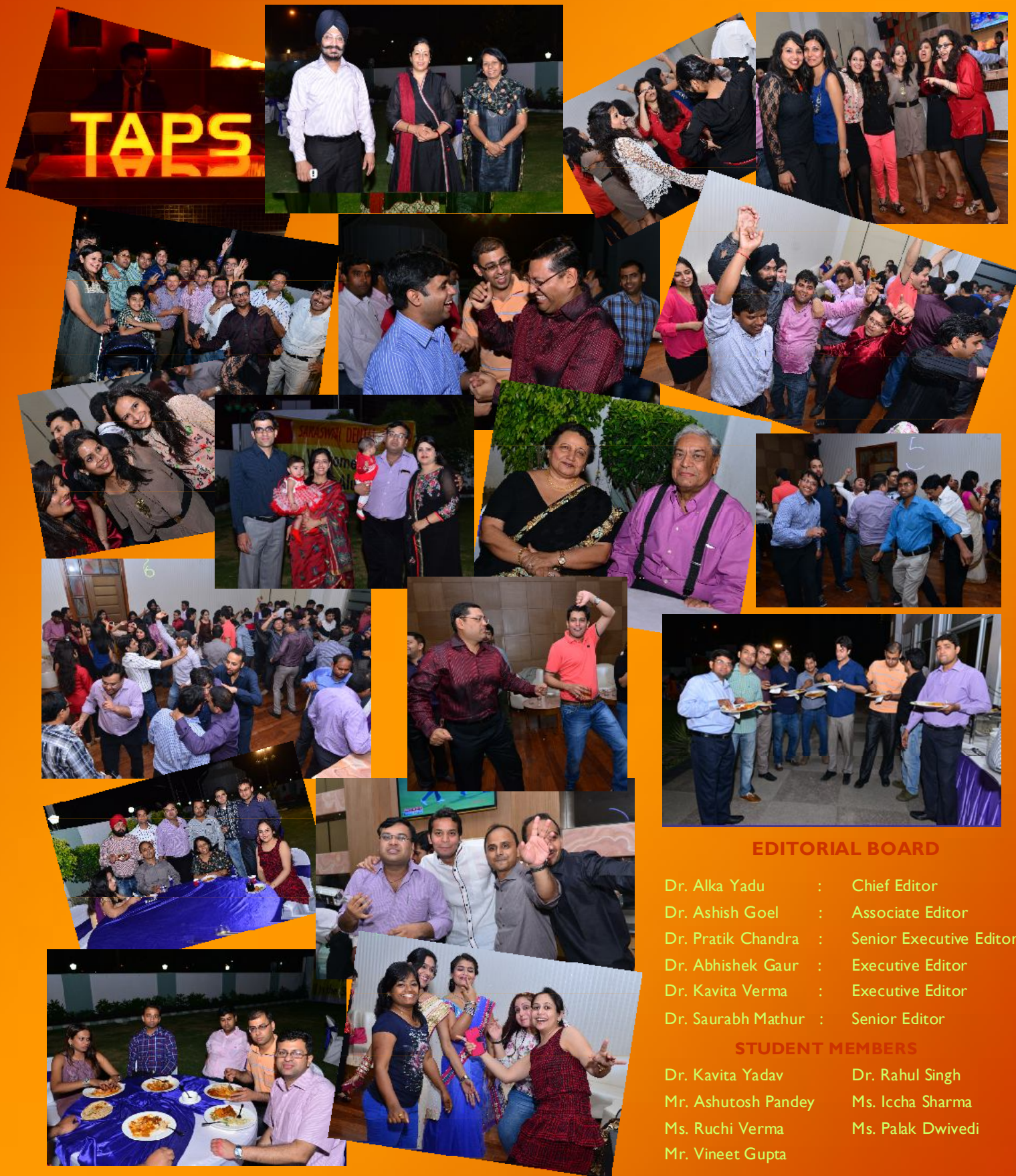VOLUME 4, ISSUE 2

# 3RD ALUMNI ASSOCIATION MEET: DAY EVENT on 29 March 2014 at SDC Auditorium





3<sup>RD</sup> ALUMNI ASSOCIATION MEET on 29 March 2014: GALA DINNER  
at TAPS, THE GRAND JBR, GOMTI NAGAR, LUCKNOW



**EDITORIAL BOARD**

Dr. Alka Yadu	:	Chief Editor
Dr. Ashish Goel	:	Associate Editor
Dr. Pratik Chandra	:	Senior Executive Editor
Dr. Abhishek Gaur	:	Executive Editor
Dr. Kavita Verma	:	Executive Editor
Dr. Saurabh Mathur	:	Senior Editor

**STUDENT MEMBERS**

Dr. Kavita Yadav	Dr. Rahul Singh
Mr. Ashutosh Pandey	Ms. Iccha Sharma
Ms. Ruchi Verma	Ms. Palak Dwivedi
Mr. Vineet Gupta	