

SARASWATI DENTAL
COLLEGE,
FAIZABAAD ROAD

SDC BULLETIN



VOLUME 1 ISSUE 2

1 MAY 2011

SPECIAL POINTS OF IN- TEREST:

- Starting of CDE programs
- Book Release
- DCI inspection in Department of Oral Medicine

INSIDE THIS ISSUE:

Book Release	2
Case of the issue	2
Suggestive Reading	2
Publications of the	3
Upcoming head- lines..	4

CONTINUING DENTAL EDUCATION PROGRAMME:



There was continuing dental education program was held on 15 January 2011 which was taken up by Dr. Arvind Tripathi P.G. Dean and Head Of Department Prosthodontics.

The lecture was very useful for various students and the guest lecturer for the day even imparted various points for clinical reference regarding the topic.






BOOK RELEASE:

The eminent professor and head of the department released a book under the publication of Jaypee Brothers. This book is an essential tool for the students preparing for their post graduation and it even provides adequate information for the students to enhance their knowledge in the field of pathology.

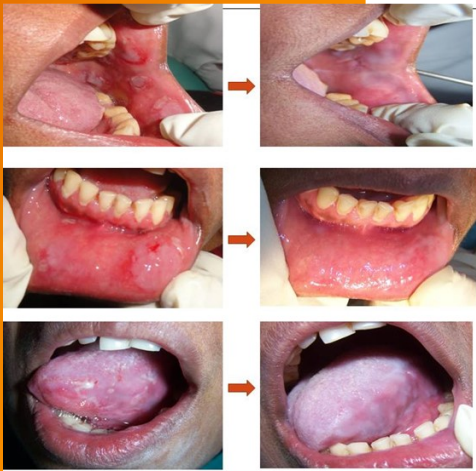This book has a foreword by Dr. Anil Kohli and has the contribution of very important and scholar people in the the field of pathology.

The book is quite handy for last minute revisions and for concept building in certain field of topics.

The book is best assured for the students preparing for post graduation.



Case of the issue::




PRE-TREATMENT

POST-TREATMENT


A case of Pemphigus in a 47-years old female patient who reported in the Department of Oral Medicine & Radiology of Saraswati Dental College, Lucknow with the chief complaint of pain & blisters in oral cavity since 6 months. She gave a history of multiple ruptured vesicles in various sites within the oral cavity which were recurrent in nature & were associated with moderate pain and difficulty while mastication. Intraoral examination revealed multiple erosions bilaterally on buccal mucosa, lower labial mucosa, left lateral border & left half of ventral surface of tongue measuring approximately 1X1.5 cm in size, tender & bled on palpation. Few petechiae were also noticed on posterior part of hard palate. Based on the history and clinical presentation, a provisional diagnosis of Erythema Multiforme was made. An incisional biopsy was done from the left buccal mucosa and the tissue was sent for histopathological analysis

Thus, the patient was advised an increased dose of systemic corticosteroids (prednisolone 40mg) along with systemic antivirals (acyclovir 200mg, four times a day) and was kept on a strict follow up for a week at which the lesions showed partial remission and after a month showed complete resolution.

Suggestive Reading ::



Two strong-willed men, a developer and a holdout, propel this gripping novel about real estate, greed and community in Mumbai (Bombay), India. There's a building in Mumbai we get to know as well as the two protagonists. Vishram Society Tower A is an unremarkable six-story structure a stone's throw from the Vakola slums. Water supply is poor. Pests necessitate visits from the "seven-kinds-of-vermin" man. Still, the building has class. The residents of this co-op are middle-class professionals, respectable people typified by Yogesh Murthy, known as Masterji, the 61-year-old retired physics teacher and recent widower. Mr. Shah is the far from respectable but hugely successful builder. His is a rags-to-riches story; starting with smuggling and slum clearance, he's now at the top of the heap. Vishram's two towers' proximity to the financial center attract his attention. They must be demolished to make way for his magnificent new project.



Publications of the issue:

BOOK CHAPTERS

Saxena SK, Tiwari S, Saxena R, Mathur A, Nair MPN. Japanese encephalitis: An emerging and spreading Arbovirosis. In Flavivirus Encephalitis, Daniel Ruzek (Ed.), InTech, Croatia (European Union), pp. 295-316, 2011

FULL LENGTH PUBLICATIONS

Agarwal P, Upadhyay U, Tandon R, Kumar S. Nickel allergy in orthodontics. Asian J Oral Health Allied Sci 1(1):61-63, 2011.

Ahuja M, Halli RC. Microimplants - A stable source of anchorage. Asian J Oral Health Allied Sci 1(1):64-66, 2011.

Bahuguna R, Jain A, Khan SA. Knowledge and attitudes of parents regarding child dental care in an Indian population Asian J Oral Health Allied Sci 1(1):9-12, 2011

Bedi RS, Verma P, Goel P, Kathuria P. Radiographic Comparison of the two Standardized Implants with single Wide Diameter Implant for Replacement of one Mandibular Molar. Asian J Oral Health Allied Sci 1(1):4-8, 2011

Gaur TK. Bent needle technique for blocked anesthesia – A modified approach. Asian J Oral Health Allied Sci 1(1):79-82, 2011. Upadhyay U, Agarwal P, Loomba A, Hivalekar A. Friction: An overview. Asian J Oral Health Allied Sci 1(1):55-57, 2011.

Vats A, Punja A, Hegde P, Hegde MN, Bains R, Loomba K. Evaluation of effect of root canal preparation techniques on inducing root fractures: An in vitro study. Asian J Oral Health Allied Sci 1(1):17, 2011.

Vohra P, Vohra N. Provisional prosthesis for class 1 Radical Mandibular Alveolectomy patient: A case report. Asian J Oral Health Allied Sci 1(1):35-39, 2011.

Loomba A, Goel A, Mehta P, Sohal V. A. Clinical application of loops in orthodontics. Asian J Oral Health Allied Sci 1(1):53-54, 2011

Reddy UCHU, Jyothirmal J. Cone beam Computed Tomography and Dental Implications. Asian J Oral Health Allied Sci 1(1):77-78, 2011

Loomba A, Bains R, Loomba K, Ganesan S, Bains VK. Sinus tract mimicry: A case report. J Oral Health Comm Dent 5(1):52-55, 2011.

Loomba A, Goel A, Goel P, Loomba K. In vitro biocompatibility of stainless steel brackets. J Int Coll Dent India, Sri Lanka & Nepal 56(1&2):21-24, 2011.

Nayak M, Chandra S, Singh A, Astekar M. Keratoacanthoma of lip. Internat J Dental Clin 3:101-102, 2011.

Raj V, Mahajan S. Dose response relationship of nuclear changes with fractionated radiotherapy in assessing radiosensitivity of oral squamous cell carcinoma. J Clin Exp Dent 3:e193-e200, 2011.

Singh BP, Makker A, Tripathi A, Singh MM, Gupta V. Association of testosterone and bone mineral density with tooth loss in men with chronic periodontitis. J Oral Sci 53(3):333-339, 2011.

Singh D, Agarwal S, Shashikanth MC, Deepak U, Mehra A. Angina bullosa hemorrhagica: A case report. Asian J Oral Health Allied Sci 1(4):1-3, 2011.

Singh GP, Rizvi I, Gupta V, Bains VK. Influence of smokeless tobacco on periodontal health status in local population of North India: A cross-sectional study. Dental Res J 8(4):211-220, 2011

DCI Inspection in Department of ORAL MEDICINE.



Welcome of the inspectors by Dr. Anjali Seth



Dr. Saubah Matur, Dr. T.K. Gaur answering various queries by the inspectors.

Upcoming Events ...

1. DCI Inspection in department of Conservative Dentistry.
2. NSK Equipment Maintenance Training Program.
3. Reporting of new BDS batch (2011-2012)
4. CDE Program on Minimal Invasive Dentistry.



Warm welcome by Dr. Rhythm Bains and Dr. Atul Gupta. (Department of Conservative Dentistry)

THE EDITORIAL BOARD ::

Dr. Alka Yadu
Dr. Pratik Chandra
Dr. Saurabh Mathur
Dr. Abhishek Gaur

Disha Goyal
Sneha Mehrotra
Ashutosh Pandey
Neha Bajpai
Paridhi Mehra
Mithali Kaushik
Nitin Jhunjhunwala