

SARASWATI DENTAL  
COLLEGE,  
FAIZABAAD ROAD

# SDC BULLETIN



1 JAN 2013

## SPECIAL POINTS OF IN- TEREST:

- Visit by Kamal Hasan
- Talent Hunt
- Inter city Rctract meet
- Collaboration with big bazaar for dental camp

## INSIDE THIS ISSUE:

- Publications of the issue 2
- Case of the issue 2
- Suggestive Reading 2
- Collaboration with big bazar 3
- Creative Writing 3
- Upcoming head- lines.. 4

## PRE— LAUNCH OF VISHWAROOPAM

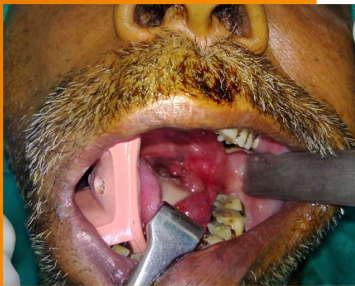

Film actor and director Mr. Kamal Hasan visited the college for the pre launch of their film Vishwaroopam accompanied by Miss Pooja Kumar.  
Photos: Top : Dr. (Col.) T.S. Mathur, Charit Mathur, Ritu Mathur, Miss Pooja Kumar, Mr. Kamal Hasan.

## Publications of the issue:

- Chandra P, Agarwal S, Singh D, Agarwal S. Intra oral molar distalization - A review. *J Dentofac Sci* 1(1):15-18, 2012.
- \Singh R, Tripathi A, Singh JP, Singh GP, Singh T. Use of Custom Adapted Broderick Occlusal Plane Analy zer (BOPA) to a Hanau-H2 Articulator in rehabilitation of a complex partial edentulous situation. *Asian J Oral Health Allied Sci* 2(1):49-54, 2012
- Goel A, Loomba A, Goel P, Goel P, Mathur R, Tandon R. Obstructive Sleep Apnea: An overview. *Asian J Oral Health Allied Sci* 2(1):26-30, 2012.
- Golwara A, Azam A, Chandra S. Adult orthodontics: Strategic treatment in the face of existing periodontal disease. *J Clin Res Dent* 3(5):25-27, 2012.
- Gupta VK, Malhotra S. Pharmacological attribute of *Aloe vera*: Revalidation through experimental and clinical studies. *AYU (An International Quarterly Journal of Research in Ayurveda)* 33(2):193-196, 2012
- Jain A, Tyagi P, Khan SA, Jain M, Agarwal A. Prevalence of dental caries and dental fluorosis amongst children of low, moderate and high fluoride areas in Lucknow district of Uttar Pradesh: A clinical survey. *J Indian Assoc Public Health Dent* 20:66-71, 2012.
- Kabra P, Loomba K, Kabra SK, Majumdar DSP, Kumar N. Medicinal plants in the treatment of dental caries. *Asian J Oral Health Allied Sci* 2(1):12-16, 2012.
- Kar S, Tripathi A. Removable partial dentures for a patient with ectodermal dysplasia: A clinical report. *Indian J Dent*, 2012 (published online: <http://dx.doi.org/10.1016/j.ijd.2012.07.02>, pp. 1-4).
- Loomba K, Bains R, Bains VK, Loomba A, Nadig RR, Shrivastava TV. Tissue engineering and its application in endodontics: An overview. *Endodont Pract Today* 6(2):105-112, 2012.
- Mishra G, Shaikh H. Prevalence of periodontal disease among engineering students in the Lucknow city (U.P.). *J Indian Acad Dent Special Res* 1(3):6-9, 2012.
- Pasricha N, Gupta A, Nagar A, Bedi RS, Siddiqui MS. Human dental stem cells: A current perspective. *Indian J Bio Res* 81(4):1-8, 2012.
- Rajguru JP, Somayaji NS, Babu NA, Masthan KMK, Khare P. Study of palatal rugae pattern (Rugoscopy) in Chennai population. *Indian J Forens Odontol* 5(3):93-96, 2012.
- Rastogi A, Srivastava S. Digital impressions. *Indian Dent J* 4:35-37, 2012.
- Srivastava SC, Verma K, Chandra P, Agarwal S. Acrylic ball end clasp for retention of removable orthodontic appliances. *J Dentofac Sci* 1(2):37-38, 2012.
- Tiwari S, Chitti SVP, Mathur A, Saxena SK. Japanese encephalitis virus: An emerging pathogen. *Amer J Virol* 1(1):1-8, 2012

## Case of the issue::

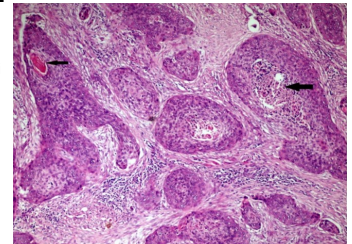


Intraoral presentation

### Basaloid Squamous Cell Carcinoma: A Rare and Aggressive Variant of Squamous Cell Carcinoma

A 60 year old man reported with a painful swelling on the left side of the neck. He gave history of beedi smoking since 30 years, with a frequency of 10-12 / day and gutkha chewing for the same period of time with a frequency of 3- 5 packets per day.


Intra oral examination revealed ulcero-proliferative lesion over the posterior part of lateral border of tongue and extending over the palate (Fig 1) .Histopathological examination revealed biphasic pattern (squamous and basaloid) showing dysplastic epithelium invading connective tissue confirmed in the form of nests, islands and lobules. A few areas showed epithelial cells proliferating in the form of cords interconnecting with each other (Fig 2). Based on the histopathological features, final diagnosis of basaloid squamous cell carcinoma was made. Level I, Level II, Level III lymph nodes also showed metastatic involvement. Debulking surgery was done to reduce the size of the tumor and patient was referred for radiotherapy and chemotherapy. Patient was followed up for 6 months. Patients is responding well to the treatment.




Histopathological presentation (Low power)

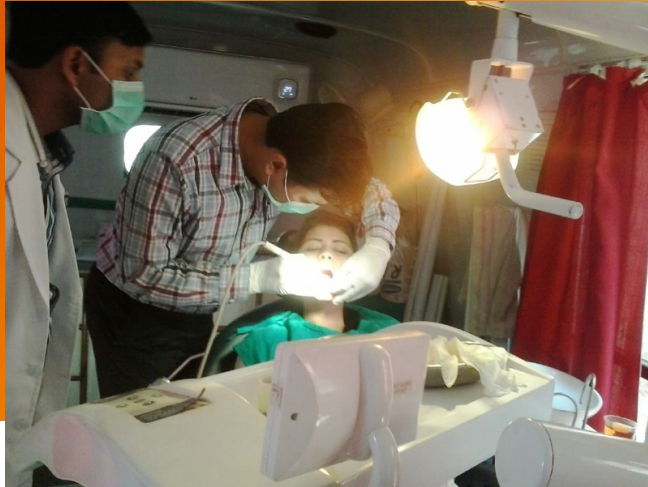## Suggestive Reading ::

Seventeen year-old Veronica “Ronnie” Miller’s life was turned upside-down when her parents divorced and her father moved from New York City to Wilmington, North Carolina. Three years later, she remains angry and alienated from her parents, especially her father... until her mother decides it would be in everyone’s best interest if she spent the summer in Wilmington with him. Ronnie’s father, a former concert pianist and teacher, is living a quiet life in the beach town, immersed in creating a work of art that will become the center piece of a local church. The tale that unfolds is an unforgettable story about love in its myriad forms – first love, the love between parents and children – that demonstrates, the many ways that deeply felt relationships can break our hearts... and heal them.





# DIAGNOSOTIC CAMP IN COLLABORATION WITH BIG BASZAAR



**BIG BAZAAR**  
Is se *sasta* aur *accha* kahin nahi!

Saraswati Dental College & Hospital and Saraswati Hospital & Research Centre are conducting Diagnostics Camp in collaboration with Big Bazaar at five locations in Lucknow City simultaneously.

From- 8<sup>th</sup> Dec. to 24<sup>th</sup> Dec. 2012, Timings-11:00 AM to 9:00 PM.

1. Indira Nagar (Saraswati City Office)
2. Gomti Nagar (INOX Mall)
3. Kanpur Road (Phoenix Mall)
4. Kaiserbagh (Anand Cinema)
5. Hazratganj (Sahara Ganj)

## DISCOVERY

Today I smiled, and all at once  
Things didn't look so bad.  
Today I shared with someone else,  
A bit of hope I had .  
Today I sang a little song, and felt my heart grow light  
And walked a happy little mile , with not a cloud in sight.  
Today I loved a little more , complained a little less ,  
And in the giving of myself, Forgot my Lonliness.....



# FRESH FACE HUNT IN LUCKNOW::



## Upcoming Events ...

1. Inauguration of Geriatric Oral Health unit .
2. Laptop distribution
3. Visit by DCI President
4. CDE Programme
5. Inauguration of Amphitheatre



Shobhit in the question answer round of the talent hunt organized by M.B Club Lucknow.

## THE EDITORIAL BOARD :-

Dr. Alka Yadu  
Dr. Pratik Chandra  
Dr. Saurabh Mathur  
Dr. Abhishek Gaur

Disha Goyal  
Sneha Mehrotra  
Ashutosh Pandey  
Neha Bajpai  
Paridhi Mehra  
Mithali Kaushik  
Nitin Jhunjhunwala